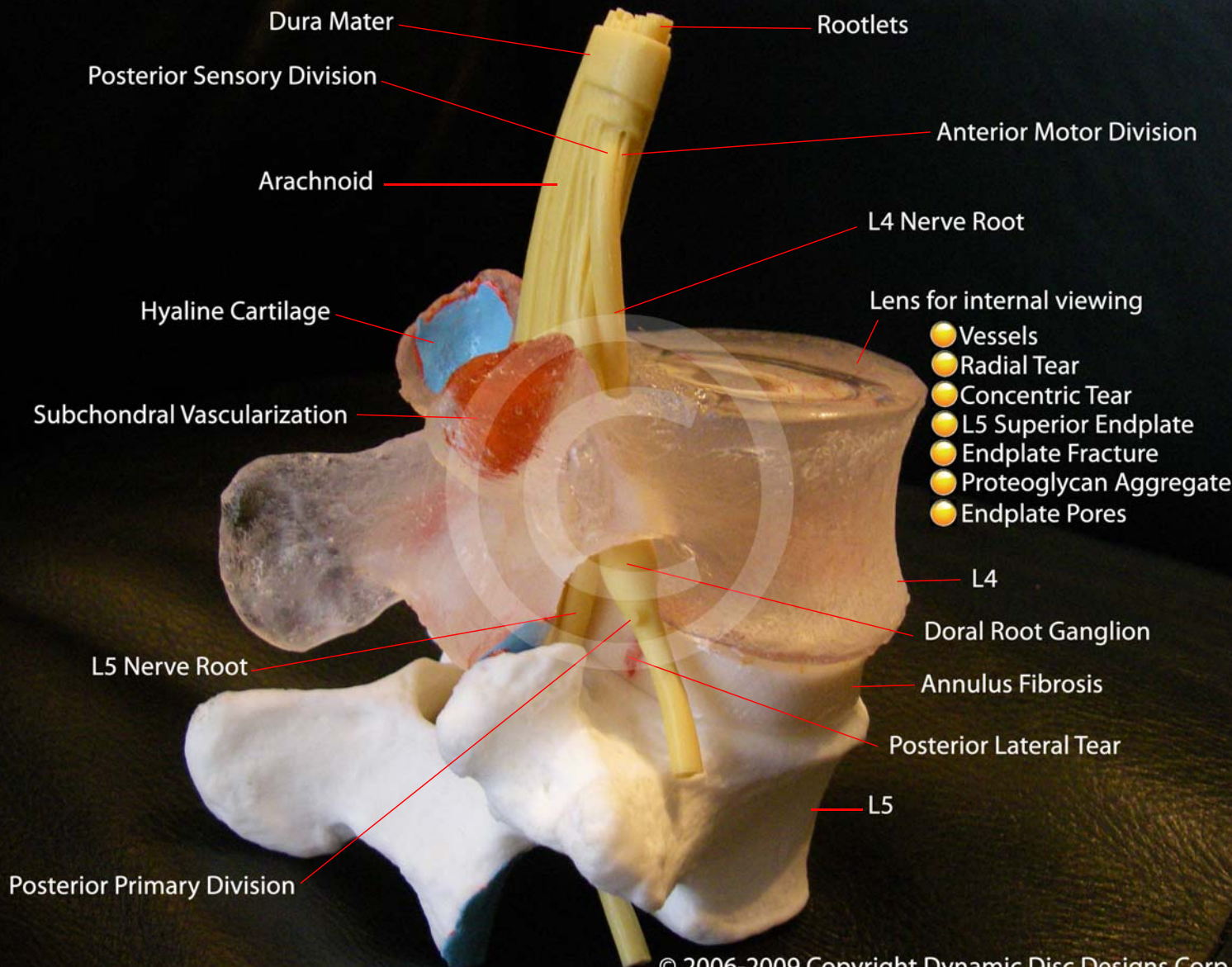

L4

Sinuvertebral Nerve (with professional model)

Concentric Tear

Radial Tear

Inner Annular Injury  
(with professional model)

Neo-innervation  
(with professional model)

Annulus Fibrosus

Embedded Nuclear Proteoglycan

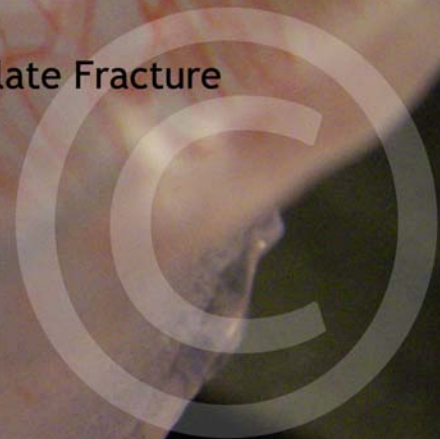
Nucleus Pulposus


Endplate Hyaline

Endplate Fracture

Endplate Pores

Concentric Tear on Anterior Annulus  
(with professional model)





Subchondral Vascularization

L4

Hyaline Cartilage

L4 Dorsal Root Ganglion

Posterior Primary Division

Motor Division

Branch from Recurrent Meningeal

L5 Nerve Root

Branch from Gray Rami Communicans

Full Annular Tear

L5

IVD